

**PATIENT**

Sophie Mattheu

SPECIES

Canine

BREED

Mix

SEX

Female Spayed

AGE

1.1.11

WEIGHT

25lbs

PRESENTING CLINICAL SIGNS

History: Recheck echo. Patient presented for exam and vaccines. Owner reported that Sophie has had a recent onset of PU/PD, new cough and weight loss. Physical exam- heart murmur, loss of body condition.

-Pertinent abnormal PE/Chem/CBC/UA Results: Increased ALT and WBC.

-Radiographs: Cardiomegaly, hepatomegaly.

-Sedation used: Not required to complete full diagnostic ultrasound.

-Pertinent previous ultrasound results (5/15/2018): CVD B1.

-STAT: Not requested

-Imaging performed by: Stephanie Pearce RDCS, RVT.

ECHOCARDIOGRAM FINDINGS

2D, m-mode, color flow and doppler imaging is available. The mitral valve is diffusely thickened with significant prolapse into the left atrial lumen. Flail anterior leaflet. There is marked mitral regurgitation present. There is marked left atrial enlargement. There is severe left ventricular dilation. Left ventricular systolic function is hyperdynamic. There is normal systolic flow velocity across the aortic valve. The aortic valve appears trileaflet with normal mobility. The main pulmonary artery is dilated. Moderate right atrial and right ventricular dilation. Mild right ventricular hypertrophy. The tricuspid valve is thickened with moderate tricuspid regurgitation. The tricuspid regurgitant velocity is elevated; PG >70mmHg. No aortic and mild pulmonic insufficiency. No pericardial/pleural effusion or cardiac masses are seen.

CARDIAC CHART**INTERPRETED BY**

Maggie Machen Lamy,
DVM, DACVIM
(Cardiology)

HOSPITAL NAME

Hickory Veterinary
Hospital

REFERRING VET

Dr. McNesby

INVOICE

23336

DATE

3.29.22

CANINE CARDIAC PARAMETERS	MR VMAX (m/s)	TR VMAX (m/s)	LA/AO (Boon method)	LA/AO (Heart Base; Swe)	FS (%)	EF (%)	EPSS (cm)
NORMAL PARAMETER	4.5-5.5	<2.7	1.3	<1.6	28-40	40-100	<0.6
PATIENT	4.7	4.2	NM	2.7	44	75	NM
CANINE CARDIAC PARAMETERS	HR (BPM)	AV VMAX (m/s)	PV MAX (m/s)	BODY WEIGHT (kg)	LA 2D short axis Base view (cm)	LVIDd Avg; 2D and m-mode short axis (cm)	LVIDs Avg; 2D and m-mode short axis (cm)
NORMAL PARAMETER	50-100	0.7-1.7	0.7-1.6	BELOW	BELOW	BELOW	BELOW
PATIENT	160	0.93	0.8	11.3	4.0	4.5	2.5
*Normal chamber parameters expressed as a mean value (SD)				3	1.27 (5.3)	2.46 (2.46)	1.36 (5.5)
BODY WEIGHT DEPENDENT PARAMETERS				5	1.40 (4.5)	2.74 (5.2)	1.60 (4.7)
<i>*Note: All measurements based upon multi-modal images and methods. An average value is reported.</i>				10	1.50 (3.8)	3.27 (3.5)	2.06 (3.1)
				15	1.83 (2.0)	3.71 (2.4)	2.43 (2.1)
				20	2.02 (1.9)	4.14 (2.2)	2.80 (2.0)
				25	2.18 (2.4)	4.48 (2.9)	3.10 (2.5)
				30	2.33 (3.3)	4.83 (3.9)	3.39 (3.4)
				35	2.48 (4.3)	5.17 (5.0)	3.69 (4.5)
				40	2.62 (5.2)	5.48 (6.1)	3.96 (5.4)
				50	2.88 (7.1)	6.07 (8.3)	4.46 (7.4)

Adapted from June Boon, Veterinary Echocardiography, 1998
Rishniw M and Hollis NE, J Vet Intern Med 2000; 14:429-435
Hansson et al, Vet Rad and Ultrasound 2002
Bonagura et al. Echocardiography: principles of interpretation, Vet Clin North Am 15:1177, 1995

INTERPRETATION OF THE FINDINGS & FURTHER RECOMMENDATIONS

Chronic degenerative valve disease persists with significant progression. Mild disease has become severe with severe mitral and moderate tricuspid regurgitation. This is not surprising given the time frame. Severe left atrial and ventricular enlargement indicate the risk for spontaneous congestive heart failure is elevated. There is also concurrent significant pulmonary hypertension and right heart enlargement, which may indicate underlying pulmonary pathology as well in this coughing patient. Initiation of full cardiac support is recommended at this time as below including both diuretics and Sildenafil, given a high risk for decompensation.

A cough in this patient with severe heart disease is likely multi-factorial in origin, however there is concern for progression to early CHF in this patient. Additional multi-factorial reasons include mainstem bronchi compression, and/or some degree of lower airway disease given the degree of right heart changes. With this degree of pulmonary hypertension sildenafil is indicated as below. Pending response to diuretic and supportive cardiac therapy, cough suppression (hydrocodone up to q4-6 hours) may also be helpful for QOL. Monitoring of sleeping breathing rates is recommended as the best way to screen for CHF at home.

The average survival of canine patients with this severity of disease and concern for CHF is 8-9 months on medications, however they generally are able to maintain a good quality of life. Going forward the risk will remain high for CHF (right or left-sided), development of arrhythmias/syncope and/or sudden death, and close monitoring is advised.

Elective anesthesia is not advised.

Omega fatty acid supplementation and mild salt restriction may also be of some long-term benefit. Monitor for development of a worsening cough, labored breathing, abdominal distention, exercise intolerance or collapse episodes. Monitoring of sleeping breathing rates is the best way to assess for development of cardiogenic edema going forward.

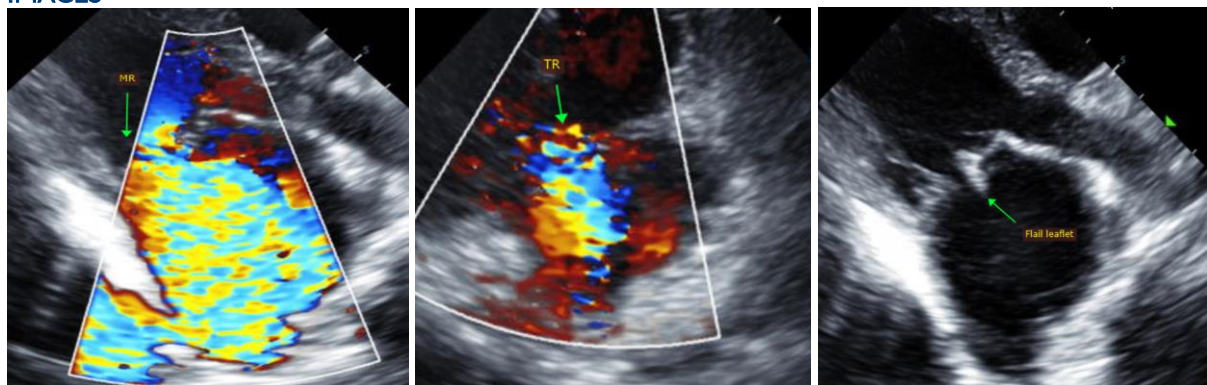
PLAN

Institute Lasix 1-2mg/kg PO q12h. Institute Pimobendan 0.3mg/kg PO q12h. Institute spironolactone 12.5mg PO q12h. Institute Sildenafil 1-2mg/kg PO q12h. If indicated, consider hydrocodone with homatropine, .2-.4mg tabs, PO up to q4-6 hours PRN. Pending BP >130mmHg, continue ACEI 0.5mg/kg PO q12h.

A renal panel is recommended in 10-14 days to ensure tolerance of medications, then every 3-4 months lifelong.

A recheck echocardiogram is recommended in 4-6 months to screen for progression, sooner if clinical signs arise/persist.

IMAGES



The information and recommendations provided are based on the images presented by the referring veterinarian. No evaluation can be communicated regarding pathology that was not visible in the image/video clips provided.

Thank you for this referral. This report was generated using transcription software, and minor dictation errors may be present. If the clinical or image interpretation does not parallel your findings or if I can be of any further assistance, please contact me.

Maggie Machen Lamy, DVM
Diplomate of the American College of Veterinary Internal Medicine (Cardiology)
info@sonopath.com